

Bacteriological analysis of necrotic pulp and fistulae in primary teeth

Antônio Scalco FABRIS, Viviane NAKANO, Mario Julio AVILA-CAMPOS

Anaerobe Laboratory, Department of Microbiology, Institute of Biomedical Sciences, University of São Paulo, SP, Brazil.

Corresponding address: Dr. Mario Julio Avila-Campos - Departamento de Microbiologia, Instituto de Ciências Biomédicas, Universidade de São Paulo - Av. Prof Lineu Prestes, 1374 - sala 242 - 05508-900 - São Paulo - SP - Brazil - Phone/fax: 55 11 3091-7344/7354 - e-mail: mariojac@usp.br

Submitted: June 13, 2013 - Modification: December 23, 2013 - Accepted: January 13, 2014

ABSTRACT

Objectives: Primary teeth work as guides for the eruption of permanent dentition, contribute for the development of the jaws, chewing process, preparing food for digestion, and nutrient assimilation. Treatment of pulp necrosis in primary teeth is complex due to anatomical and physiological characteristics and high number of bacterial species present in endodontic infections. The bacterial presence alone or in association in necrotic pulp and fistula samples from primary teeth of boys and girls was evaluated. **Material and Methods:** Necrotic pulp (103) and fistula (7) samples from deciduous teeth with deep caries of 110 children were evaluated. Bacterial morphotypes and species from all clinical samples were determined. **Results:** A predominance of gram-positive cocci (81.8%) and gram-negative *coccobacilli* (49.1%) was observed. In 88 out of 103 pulp samples, a high prevalence of *Enterococcus* spp. (50%), *Porphyromonas gingivalis* (49%), *Fusobacterium nucleatum* (25%) and *Prevotella nigrescens* (11.4%) was observed. *Porphyromonas gingivalis* was detected in three out of seven fistula samples, *Enterococcus* spp. in two out of seven samples, and *F. nucleatum*, *P. nigrescens* and *D. pneumosintes* in one out of seven samples. **Conclusions:** Our results show that *Enterococcus* spp. and *P. gingivalis* were prevalent in necrotic pulp from deciduous teeth in boys from 2 to 5 years old, and that care of the oral cavity of children up to five years of age is important.

Keywords: Necrotic pulp. Primary teeth. *Enterococcus* spp. *P. gingivalis*. Children.

INTRODUCTION

Since primary teeth work as guides for the eruption of permanent dentition and contribute to the development of jaws, chewing process, preparing food for digestion and nutrient assimilation, they are important for childhood. Premature loss of teeth can produce change in the eruption guide of the permanent tooth, which can cause phonetic disturbances and harmful oral habits, such as tongue interposition, and aesthetic consequences³.

Dental biofilm on occlusal surfaces of primary teeth is associated to active carious lesions². The exposure of pulp tissue to the oral environment will allow that oral microorganisms have access into pulp chamber, producing necrosis¹⁰.

The treatment of pulp necrosis, particularly in primary teeth, is very complex due to anatomical and physiological characteristics, making the access to the root canal difficult¹³. Treatment of primary

endodontic infections is based on the elimination of the root canal infection; although no protocol or techniques for canal instrumentation have been observed¹⁶. Bacterial species such as *Enterococcus faecalis* has been reported in high prevalence in primary endodontic infections affecting Turkish children¹⁵.

The presence of different bacteria involved in endodontic infections of primary teeth, such as pulpitis, pulp necrosis and apical lesion has been reported^{17,20,21}; however, microbiological data of fistula are scarce.

Anaerobic bacteria, especially black-pigmented gram-negative rods, are implicated in the development of the acute periradicular inflammation, producing symptoms such as pain, swelling, tenderness and exudation¹². Microorganisms found in the root canals of primary teeth are similar to those in the root canals of permanent teeth, and black-pigmented anaerobes have been isolated

(30% to 50%) from endodontic infections²⁴, but no relationship between any bacterial species and the etiology of pulp infection have been showed, although there is evidence that black-pigmented anaerobes are implicated in the development of acute periradicular inflammation²⁶. In this study, the bacterial presence and the different morphotypes in necrotic pulp and fistula from primary teeth were determined.

MATERIAL AND METHODS

Patients and clinical samples

A total of 110 children (69 boys and 41 girls), aged from 2 to 12 years old, with clinical and radiographic signs of necrotic pulp or fistula, observed at the School of Dentistry of the Federal University of Espírito Santo (Vitória, ES, Brazil), were selected. All children presented primary teeth with deep dental caries and dental pulp exposed to oral environment. Some children presented vestibular fistula in gingival area. A single clinical sample was collected *per* child. No child used antibiotics at least three months prior to the sample collection. Children presenting intact teeth, dental pain at oral examination or any chronic disease were excluded.

Necrotic pulp samples (35 maxilla and 68 mandible region) from 103 children, and gingival fistulas (6 maxilla and 1 mandible region) from 7 children were collected. Necrotic pulp or fistula samples were collected by using two sterile paper points (Nº. 15, Dentsply, Petrópolis, RJ, Brazil). Initially, tooth and pulp chamber were isolated by rubber dam and the tooth and the surrounding field were cleansed with 3% hydrogen peroxide and decontaminated with a 1% sodium hypochlorite solution for 1 min. The sterility of the tooth surface after cleaning and disinfection was evaluated by samples taken from the surface and processed by PCR. Before collecting fistula sample, antisepsis with iodine (2%) for 1 min was performed. Sodium hypochlorite and iodine solutions were neutralized with sodium thiosulfate (5%) for 30 s. In dry root canal, one drop of sterile saline (0.9%) was added, avoiding flooding²⁷. The paper points were left in wet canal for 60 s and then transferred to tubes containing 250 µL of TE. All clinical samples were analyzed within 4 h after collection. All children's guardians signed a consent form approved by Committee for Ethics in Human Research of the Institute of Biomedical Sciences, University of São Paulo (Process Nº CEH/678).

Bacterial morphotypes from pulp necrotic and fistula samples

Bacterial morphotypes were directly determined from collected samples by using Gram and Brown-Brenn staining. The stained smears were observed

and photographed with a light microscopy (1000 X DMIL Leica, Wetzlar, Germany).

Bacterial DNA detection from pulp and fistula samples

Clinical samples were collected and resuspended in 100 µL of sterile ultrapure water (Milli-Q, Millipore, Bedford, MA, USA) and boiled for 10 min. After centrifugation, the supernatant (DNA) was obtained and stored at -80°C. DNA concentration and purity were determined by spectrophotometer (A_{260nm}) and electrophoresis in 1% agarose gel.

PCR assays were performed in a thermal cycler (Perkin Elmer Gene Amp PCR System 2400, Norwalk, CT, USA) with final volumes of 25 µL containing 1X PCR buffer, 0.2 mM of dNTP mixture, 0.4 µM of each primer, 50 mM MgCl₂, 0.5 U Platinum *Taq* DNA polymerase (Invitrogen do Brasil, Sao Paulo, SP, Brazil), and 1 ng DNA. The respective primers, amplification conditions, and amplicon sizes are described in Table 1. A universal primers pair was used to verify the presence of DNA in all samples.

PCR products were analyzed by electrophoresis (70 V, 2 h) in 1% agarose gel visualized and photographed under UV light. 1-kb DNA ladder was used as molecular marker. DNA from *Enterococcus faecalis* ATCC 29212, *Aggregatibacter actinomycetemcomitans* ATCC 29522, *Fusobacterium nucleatum* ATCC 25586, *Porphyromonas gingivalis* ATCC 33277, *Porphyromonas endodontalis* ATCC 35406, *Prevotella intermedia* ATCC 25611, *Prevotella nigrescens* ATCC 33563, *Dialister pneumosintes* ATCC 33048, *Tannerella forsythia* ATCC 43037, *Eikenella corrodens* ATCC 23834, *Treponema denticola* ATCC 33520, and *Campylobacter rectus* ATCC 33238 were used as positive controls. In all PCR reactions, sterile water was used as negative control instead of DNA.

Statistical analysis

The cumulative frequency of distribution and chi-square test were used to verify the bacterial occurrence vs. age and sex. *P*-values less than 0.05 were considered as statistically significant.

RESULTS

In this study, the lower molar teeth showed a high incidence of pulp necrosis (66%), followed by upper molars (24.1%) and incisors (4.7%). The presence of fistulas was often observed at upper molars (57.4%), followed by lower molars (28.6%) and upper central incisor (14.3%). *Enterococcus* spp. and *P. gingivalis* were prevalent in necrotic pulp of children from 2 to 5 years old, followed by children from 6 to 9 years and 10 to 12 years old. High bacterial numbers showing statistically significant values among boys from 6 to 9 years old

($P=0.0520$) and from 10 to 12 years ($P=0.0261$) were observed (Table 2).

Different bacterial morphotypes in necrotic pulp and fistula samples were observed. Gram-positive cocci were predominant (81.8%), followed by gram-negative coccobacilli (49%) and gram-positive bacilli (15.5%) (Figure 1A). In addition, the occurrence of gram-positive cocci and gram-negative coccobacilli did not present statistically significant values for

sex or age ($P=0.7380$). Associations of different bacterial morphotypes were also observed (Figure 1B).

Bacterial DNA was detected in 88 out of 103 necrotic pulps and in 7 fistula samples by using the universal primers. In necrotic pulp samples, *Enterococcus* spp. (50%), *P. gingivalis* (48.9%) and *F. nucleatum* (25%) were predominantly found (Figure 2A). The occurrence of *Enterococcus*

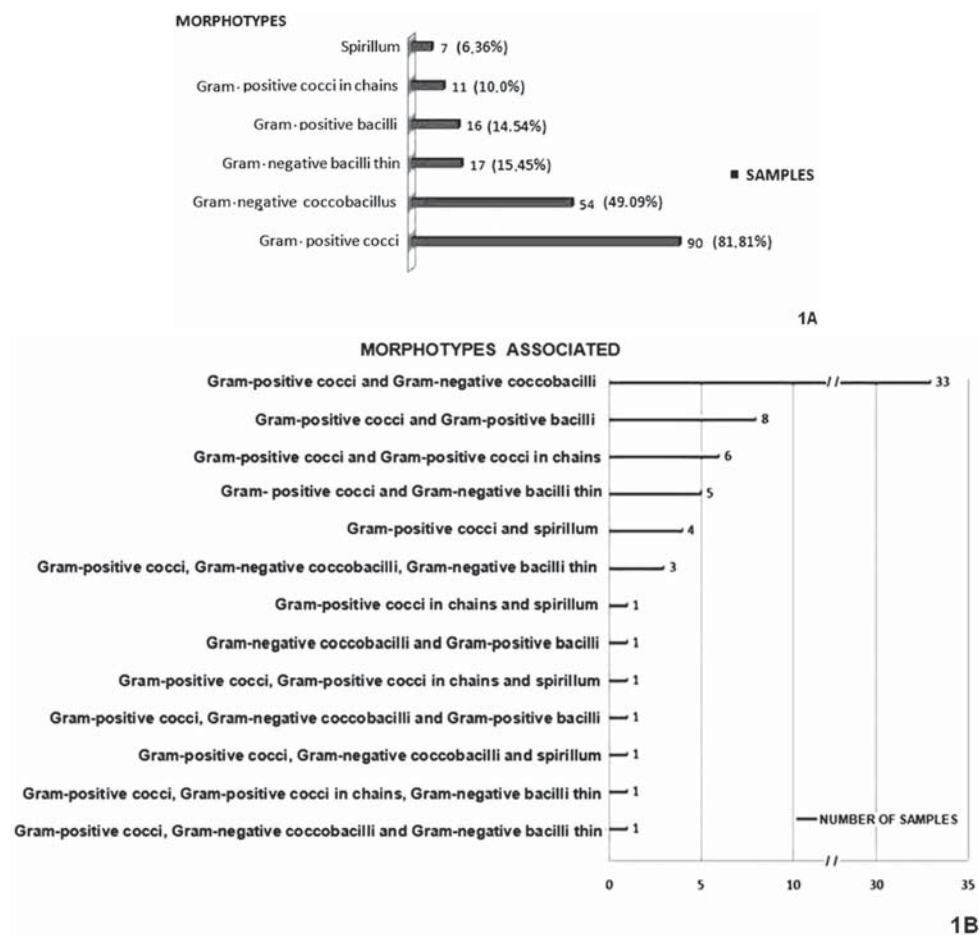
Table 1- Species-specific primers and amplification conditions used for bacterial detection

Microorganisms	Sequence 5'----->3'	Amplicon	Amplification cycles	Reference
<i>Prevotella intermedia</i>	TTT GTT GGG GAG TAA AGC GGG TCA ACA TCT CTG TAT CCT GCG T	600	30 cycles: 94°C 30 sec 50°C 30 sec 72°C 30 sec	11
<i>Prevotella nigrescens</i>	ATG AAA CAA AGG TTT TCC GGT AAG CCC ACG TCT CTG TGG GCT GCG A	804	30 cycles: 94°C 30 sec 60°C 1 min 72°C 2 min	11
<i>Porphyromonas endodontalis</i>	GCT GCA GCT CAA CTG TAG TC CCG CTT CAT GTC ACC ATG TC	672	30 cycles: 94°C 30 sec 60°C 30 sec 72°C 30 sec	11
<i>Porphyromonas gingivalis</i>	AGG CAG CTT GCC ATA CTG CG ACT GTT AGC AAC TAC CGA TGT	404	30 cycles: 94°C 30 sec 60°C 30 sec 72°C 30 sec	11
<i>Tannerella forsythia</i>	GCG TAT GTA ACC TGC CCG CA TGC TTC AGT GTC AGT TAT ACC T	600	30 cycles: 94°C 30 sec 60°C 30 sec 72°C 30 sec	18
<i>Fusobacterium nucleatum</i>	CAA ATG CTT GTG TCA ATA ATA CT TTT AGA AGA AAT GGT AGA ATA AT	500	30 cycles: 94°C 30 sec 40°C 30 sec 72°C 30 sec	23
<i>Treponema denticola</i>	TAA TAC CGA ATG TGC TCA TTT ACA T TCA AAG AAG CAT TCC CTC TTC TTC TTA	316	30 cycles: 94°C 30 sec 60°C 30 sec 72°C 30 sec	18
<i>Eikenella corrodens</i>	CTA ATA CCG CAT ACG TCC TAA G CTA CTA AGC AAT CAA GTT GCC C	700	30 cycles: 94°C 30 sec 45°C 30 sec 72°C 30 sec	18
<i>Campylobacter rectus</i>	TTT CGG AGC GTA AAC TCC TTT TC TTT CTG CAA GCA GAC ACT CTT	600	30 cycles: 94°C 30 sec 50°C 30 sec 72°C 30 sec	18
<i>Enterococcus</i> spp.	TACTGACAAACCATTTCATGATG AACTTCGTACCAACGCGAAC	112	30 cycles: 94°C 30 sec 50°C 30 sec 72°C 1 min	12
<i>Dialister pneumosintes</i>	TTC TAA GCA TCG CAT GGT GC GAT TTC GCT TCT CTT TGT TG	1105	30 cycles: 94°C 30 sec 55°C 1 min 72°C 2 min	22
<i>Aggregatibacter actinomycetemcomitans</i>	CCG GAC GTT AGC AGG AAA TTG TAA CGC CAC ATG AAA CAC TTC	3500	30 cycles: 94°C 30 sec 56°C 30 sec 72°C 30 sec	24
16S rRNA universal primers	AGA GTT TGA TCC TGG CTC AG GGC TAC CTT GTT ACG ACT T	3480	30 cycles: 94°C 30 sec 58°C 30 sec 72°C 30 sec	8

Table 2- Bacterial detection from necrotic pulp (88) and fistula (7) samples of children

Microorganisms	Age (years) and sex						Total
	2 to 5		6 to 9		10 to 12		
	B	G	B	G	B	G	
Necrotic pulp							
<i>Enterococcus</i> spp.	15	7	8	8	4	2	44
<i>Porphyromonas gingivalis</i>	14	4	9	9	4	3	43
<i>Fusobacterium nucleatum</i>	7	4	5	4	2	0	22
<i>Prevotella nigrescens</i>	2	0	0	3	3	2	10
<i>Prevotella intermedia</i>	1	1	1	1	1	0	5
<i>Treponema denticola</i>	1	0	0	2	0	0	3
<i>Tannerella forsythia</i>	0	0	0	2	0	0	2
<i>Eikenella corrodens</i>	0	1	1	0	0	0	2
<i>Campylobacter rectus</i>	0	0	0	2	0	0	2
<i>Porphyromonas endodontalis</i>	0	0	1	0	0	0	1
Total	40	17	25	31	14	7	134
Fistula							
<i>Enterococcus</i> spp.	0	0	0	0	1	1	2
<i>Porphyromonas gingivalis</i>	1	0	0	1	1	0	3
<i>Fusobacterium nucleatum</i>	1	0	0	0	0	0	1
<i>Prevotella nigrescens</i>	0	0	0	1	0	0	1
<i>Dialister pneumosintes</i>	0	0	0	1	0	0	1
Total	2	0	0	3	2	1	8

B: boys; G: girls

**Figure 1-** Bacterial morphotypes observed in 88 necrotic pulp and 7 fistula samples. (A) Gram and Brown-Brenn staining. (B) Bacterial morphotypes in association

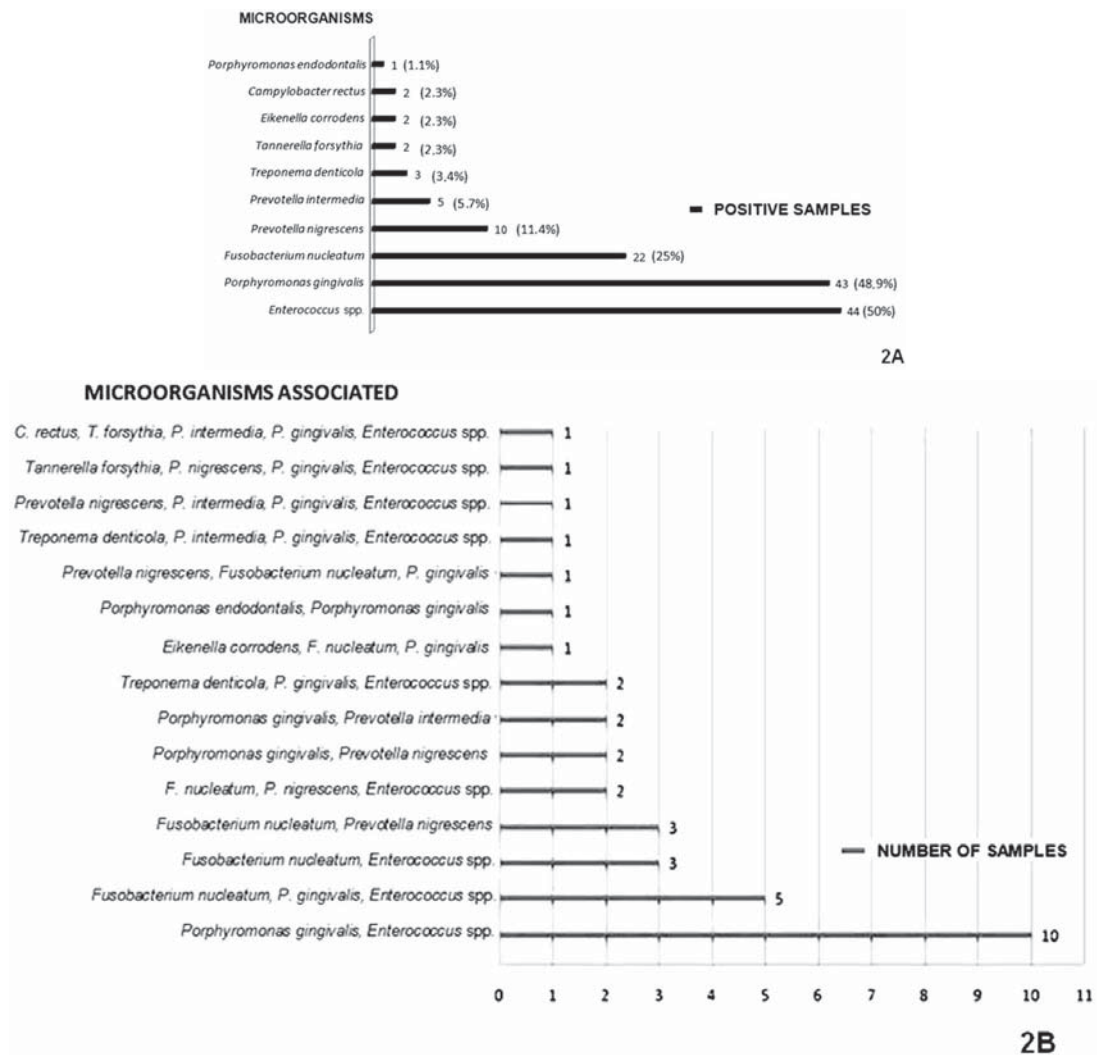


Figure 2- Bacterial detection by PCR in 88 necrotic pulps of deciduous teeth. (A) Bacteria detected. (B) Bacterial association

spp. was higher in boys than girls and presented statistically significant values ($P=0.0297$); however, no significant difference regarding age ($P=0.2994$) was observed. In Figure 2B, the bacterial associations are observed.

Three out of seven fistula samples harbored *P. gingivalis*, two samples *Enterococcus* spp., and, one sample, *F. nucleatum*, *P. nigrescens* and *D. pneumosintes*. In addition, in two fistulas, *P. gingivalis* was found associated with *Enterococcus* spp. and *F. nucleatum*, and *P. nigrescens* with *D. pneumosintes*. Pulp or fistula samples did not harbor *A. actinomycetemcomitans*.

DISCUSSION

In this study, children presented high incidence of dental caries with necrotic pulp at mandible molars. It may be explained by the food retention and poor oral hygiene in children of this age, producing large accumulation of dental biofilm².

In adults, the occurrence of bacterial morphotypes in primary endodontic infections has been described,

and they are represented by cocci, bacilli, spirillum and filamentous forms¹⁹. In children, the presence of different morphotypes in oral infections of primary teeth, such as caries followed by pulp necrosis, has also been observed²⁰. Studies have shown that in root canals of primary teeth with necrotic pulp there is predominance of anaerobic microorganisms, similar to the microbiota of permanent teeth²¹. In addition, the presence of different microorganisms in canal or necrotic pulp can represent the maintenance of infection or any synergistic infection.

Gram-positive cocci and gram-negative coccobacilli appear to be able to colonize necrotic pulp and fistula tissues alone or synergistically, and may collaborate for the maintenance of infection¹⁶. The lack of endodontic treatment may alter the development of permanent tooth and, also, increase root resorption, leading to premature loss of deciduous teeth.

Different bacterial species belonging to genera *Prevotella*, *Porphyromonas*, *Fusobacterium*, *Treponema*, *Campylobacter*, *Enterococcus*, *Tannerella* and *Dialister* have been identified in

adults with primary endodontic infections^{14,22}.

In this study, the primers used presented high sensitivity for detecting enterococci¹⁰ from root canal. The presence of *Enterococcus* spp. was observed in 50% of pulp necrotic samples, and most of them (19%) were not associated with other bacteria; it may lead to the progression of a chronic disease¹⁴. On the other hand, Siqueira, et al.²⁰ (2002) identified the presence of *E. faecalis* in root canal samples (7.5%) and asymptomatic lesions (11.5%) by using a checkerboard DNA-DNA hybridization.

Studies have shown that enterococci isolated from foods are able to colonize the oral cavity, suggesting that these microorganisms can survive in dental biofilm, participating of endodontic infections^{1,25}. In addition, it was reported that *E. faecalis* isolated from necrotic root canals and fecal material of adults with endodontic infection did not present any genetic similarity, suggesting an exogenous contamination, mainly by industrial food²⁵. On the other hand, enterococci have been found in 52.5% of dairy foods, such as milk and cheese, and it was suggested that the consumption of foods containing enterococci could collaborate with the increase of *E. faecalis* in necrotic pulp; however, it is not fully defined⁶.

The high prevalence of *Enterococcus* spp. and *P. gingivalis* observed in necrotic pulp of children from 2 to 5 years old can be explained by difficulty to perform effective tooth brushing. Microbiological studies showing the bacterial prevalence in deciduous teeth with pulp infections are scarce. Since *E. faecalis* can acquire resistance to antimicrobials commonly used in endodontic treatment¹⁵, the detection of this microorganism from different endodontic infections is of interest.

The presence of black-pigmented anaerobic rods, such as *Porphyromonas* spp. and *Prevotella* spp. has been associated with primary endodontic infections and acute periradicular abscesses⁵. It may suggest a possible cross infection between root canal and periodontal pocket. In addition, several possible ways to access the pulp are suggested, such as root canals, dentin, cement, and physiological areas of root resorption¹⁴.

The presence of *P. gingivalis* has been shown in endodontic infections affecting approximately 27% of the deciduous teeth^{9,27}; however, in this study, this microorganism was observed in 49% of the analyzed necrotic pulps, and this result is similar to that found in adults²². In addition, pulp samples harbored *P. nigrescens* (11%), *P. intermedia* (6%) and *P. endodontalis* (11%), and, certainly, their association with other bacteria may contribute to the pathogenicity and maintenance of the infectious process.

Bacterial associations such as *Porphyromonas*

spp./*Prevotella* spp. and *P. gingivalis*/*Enterococcus* spp. were detected, suggesting that these microorganisms are able to survive in necrotic tissues, alone or in association. The availability of nutrients, low oxygen tension and bacterial interactions are important ecological determinants for these bacteria in root canals with necrotic pulp²⁴.

Fusobacterium nucleatum colonizes the oral cavity, and has often been isolated from primary endodontic infections in adult patients⁷. This microorganism has been found in between 4% and 18% of the pulp infections of deciduous teeth²⁷. In this study, *F. nucleatum* was found in 25% of the necrotic pulps, alone or in association with *Enterococcus* spp. and/or *P. gingivalis*. Synergistic association between *F. nucleatum* and *P. gingivalis* has been described in various forms of periodontitis, and associated to the dental biofilm formation¹⁸.

Spirochetes such as *Treponema denticola* and *Treponema socranskii* have been detected in 77% of adults with primary endodontic infections, and both bacteria are considered prevalent in these infectious processes. Species of *Treponema* have been found in 2.6% of the pulp infections of deciduous teeth²⁷. Notwithstanding, *P. gingivalis* and *Treponema* spp. are considered important microorganisms in patients with adult periodontitis²², but the presence of *T. denticola* has been detected in small proportion and in association with *P. gingivalis*, *Enterococcus* spp. or *P. nigrescens*. It is suggested that bacterial association contributes to the pathogenic biofilms formation. In this study, the low detection rate (2.3%) of *Tannerella forsythia*, *Campylobacter rectus* and *Eikenella corrodens* is in accordance with the literature¹⁷. Recently, *Campylobacter* spp. was detected in 3.3% of children with endodontic abscesses²⁷.

Dialister pneumosintes has been observed in children and young adults with gingivitis and periodontitis, as well as lung and brain abscesses, and root canal⁴. In this study, only one fistula sample harbored *D. pneumosintes* in association with *P. nigrescens*. Both microorganisms have been isolated from primary endodontic infections, mainly in periapical lesions, and their presence in association can suggest any synergistic effect in the infected sites.

Aggregatibacter actinomycetemcomitans is a capnophilic bacteria which is considered a causal agent of localized aggressive periodontitis in young adults; the absence of this bacterium in the analyzed samples can be explained by the fact that this microorganism is not able to survive in the root canal¹⁸.

Studies have associated the failure of endodontic treatment in adults with the presence of *E. faecalis*. This microorganism shows high resistance to calcium hydroxide and irrigating solutions commonly used in

endodontic treatment^{12,15}. In addition, this bacterial resistance may also occur in treatment of primary teeth, producing a persistent infection. On the other hand, it has been pointed out that some chemical substances commonly used in endodontic treatment can produce changes in the physicochemical properties of dentin, microbiota, bacterial adherence and biofilm formation⁹.

Enterococcus faecalis, *P. gingivalis* and *F. nucleatum* were found in high numbers, and their presence may contribute to the development of chronic infections, such as gingivitis or periodontitis. Since the presence of *Enterococcus* spp. and *P. gingivalis* in pulp and fistula samples from deciduous teeth was observed, a possible bacterial synergism inside the root canal is suggested, and, certainly, it might increase their resistance against the antimicrobial agents most commonly used in Pediatric Dentistry.

ACKNOWLEDGEMENTS

The authors thank Marcia Harumi Fukugaiti for her technical support. This study was supported by CNPq grant N° 143056/2006-9 and FAPESP N° 08/58738-7. During the course of this work, VN was supported by FAPESP Proc. 08/57330-4.

CONFLICTS OF INTEREST

The authors declare that there are no conflicts of interest.

REFERENCES

- 1- Al-Ahmad A, Maier J, Follo M, Spitzmüller B, Wittmer A, Hellwig E, et al. Food-borne enterococci integrate into oral biofilm: an *in vivo* study. *J Endod*. 2010;36(11):1812-9.
- 2- Braga MM, Martignon S, Ekstrand KR, Ricketts DN, Imparato JC, Mendes FM. Parameters associated with active caries lesions assessed by two different visual scoring systems on occlusal surfaces of primary molars a multilevel approach. *Community Dent Oral Epidemiol*. 2010;38(6):549-58.
- 3- Cughi AO, Bertoz FA, Mendonca MR, Santos EC. Loss of space and dental arch length after the loss of the lower first primary molar: a longitudinal study. *J Clin Pediatr Dent*. 1998;22(2):117-20.
- 4- Doan N, Contreras A, Flynn J, Slots J, Chen C. Molecular Identification of *Dialister pneumosintes* in subgingival plaque of humans. *J Clin Microbiol*. 2000;38(8):3043-7.
- 5- Fouad AF, Barry J, Caimano M, Clawson M, Zu Q, Carver R, et al. PCR-based identification of bacteria associated with endodontic infections. *J Clin Microbiol*. 2002;40(9):3223-31.
- 6- Gomes BP, Pinheiro ET, Sousa EL, Jacinto RC, Zaia AA, Ferraz CC, et al. *Enterococcus faecalis* in dental root canals detected by culture and by polymerase chain reaction analysis. *Oral Surg Oral Med Oral Pathol Oral Radiol Endod*. 2006;102(2):247-53.
- 7- Jacinto RC, Montagner F, Signoretti FGC, Almeida GC, Gomes BPFA. Frequency, microbial interactions and antimicrobial susceptibility of *Fusobacterium nucleatum* and *Fusobacterium necrophorum* isolated from primary endodontic infections. *J Endod*. 2008;34(12):1451-6.
- 8- Ito IY, Matoba F Junior, Paula-Silva FWG, Silva LAB, Leonardo MR, Nelson P Filho. Microbial culture and checkerboard DNA-DNA hybridization assessment of bacteria in root canals of primary teeth pre- and post-endodontic therapy with a calcium hydroxide/ chlorhexidine paste. *Int J Paed Dent*. 2011;21(5):353-60.
- 9- Kishen A, Sum C, Mathew S, Lim C. Influence of irrigation regimens on the adherence of *Enterococcus faecalis* to root canal dentin. *J Endod*. 2008;34(7):850-4.
- 10- Morabito A, Defabianis P. A SEM investigation on pulpal-periodontal connections in primary teeth. *ASDC J Dent Child*. 1992;59(1):53-7.
- 11- Nandakumar R, Mirchandani R, Fouad A. Primer sensitivity: can it influence the results in *Enterococcus faecalis* prevalence studies? *Oral Surg Oral Med Oral Pathol Oral Radiol Endod*. 2007;103(3):429-32.
- 12- Ohara PK, Torabinejad M, Kettering JD. Antibacterial effects of various endodontic irrigants on selected anaerobic bacteria. *Endod Dent Traumatol*. 1993;9(3):95-100.
- 13- Öncag O, Cogulu D, Uzel A. Efficacy of various intracanal medicaments against *Enterococcus faecalis* in primary teeth: an *in vivo* study. *J Clin Pediatr Dent*. 2006;30(3):233-7.
- 14- Ozbek SM, Ozbek A, Erdogaan AS. Analysis of *Enterococcus faecalis* in samples from Turkish patients with primary endodontic infections and failed endodontic treatment by real time PCR SYBR green method. *J Appl Oral Sci*. 2009;17(5):370-4.
- 15- Queiroz AM, Nelson-Filho P, Silva LA, Assed S, Silva RA, Ito IY. Antibacterial activity of root canal filling materials for primary teeth: zinc oxide and eugenol cement, Calen paste thickened with zinc oxide, Sealapex and EndoRez. *Braz Dent J*. 2009;20(4):290-6.
- 16- Rocha CT, Rossi MA, Leonardo MR, Rocha LB, Nelson-Filho P, Silva LA. Biofilm on the apical region of root in primary teeth with vital and necrotic pulps with or without radiographically evident apical pathosis. *Int Endod J*. 2008;41(4):664-9.
- 17- Ruvierre DB, Leonardo MR, Silva LAB, Ito IY, Nelson-Filho P. Assessment of the microbiota in root canals of human primary teeth by checkerboard DNA-DNA hybridization. *J Dent Child (Chic)*. 2007;74(2):118-23.
- 18- Saito Y, Fujii R, Nakagawa K, Kuramitsu HK, Okuda K, Ishihara K. Stimulation of *Fusobacterium nucleatum* biofilm formation by *Porphyromonas gingivalis*. *Oral Microbiol Immunol*. 2008;23(1):1-6.
- 19- Siqueira JF Jr, Rôças IN, Lopes HP. Patterns of microbial colonization in primary root canal infections. *Oral Surg Oral Med Oral Pathol Oral Radiol Endod*. 2002;93(2):174-8.
- 20- Siqueira JF, Rôças IN, Souto R, Uzeda M, Colombo AP. Actinomyces species, streptococci, and *Enterococcus faecalis* in primary root canal infections. *J Endod*. 2002;28(3):168-72.
- 21- Silva LAB, Nelson-Filho P, Faria G, Souza-Gugelmin MCM, Ito IY. Bacterial profile in primary teeth with necrotic pulp and periapical lesions. *Braz Dent J*. 2006;17(2):144-8.
- 22- Slots J, Ashimoto A, Flynn MJ, Li G, Chen C. Detection of putative periodontal pathogens in subgingival specimens by 16S ribosomal DNA amplification with the polymerase chain reaction. *Clin Infect Dis*. 1995;20(Suppl 2):S304-7.
- 23- Sundqvist G. Associations between microbial species in dental root canal infections. *Oral Microbiol Immunol*. 1992;7(5):257-62.
- 24- Sundqvist G, Johansson E, Sjögren U. Prevalence of black-pigmented *Bacteroides* species in root canal infections. *J Endod*. 1989;15(1):13-9.
- 25- Tronstad L, Kreshtool D, Barnett F. Microbiological monitoring and results of treatment of extraradicular endodontic infection. *Endod Dent Traumatol*. 1990;6(3):129-36.
- 26- Van Winkelhoff AJ, Carlee AW, Graaff J. *Bacteroides endodontalis* and other black-pigmented *Bacteroides* species in odontogenic abscesses. *Infect Immun*. 1985;49(3):494-7.
- 27- Yang QB, Fan LN, Shi Q. Polymerase chain reaction-denaturing gradient gel electrophoresis, cloning, and sequence analysis of bacteria associated with acute periapical abscesses in children. *J Endod*. 2010;36(2):218-23.